

Appendix A: Table 1. Comparison of clinical presentations, pre-operative imaging, surgical management and post procedure therapeutic interventions and current status of the index patients

Test Performed	Pre-operative diagnostic procedures			
	Case 1	Case 2	Case 3	Case 4
Age/ GP Score	44 y/o G3P3 (3002)	58 y/o G3P3 (3003)	71 y/o G1P1 (1001)	66 y/o G1P1 (1000)
Clinical presentation	Recurrent vaginal discharge for 3 months with no other associated signs and symptoms. Work up done and was unremarkable. A left supraclavicular mass then noted after 6 months.	Vaginal spotting for 4 months with associated weight loss	2 months history of gradually enlarging abdomen with associated dysuria and decreased urine output. Followed by vaginal discharge after one month.	3 months history of gradually enlarging abdomen with associated change in bowel movement
Preoperative Imaging	(CT Scan) Retroperitoneal lymphadenopathy, may be metastatic. Soft tissue ovoid nodule (measuring 2.5x2.5cm, slightly in homogenous) intimately adjacent to the left ovary (measures 2.1x2.9cm and shows several thin-walled cystic foci of varying sizes) and the left lateral uterine wall. Differentials may include a left ovarian new growth versus subserous myoma.	(CT Scan) Pelvic mass that may represent new growth of ovarian etiology, solid heterogeneously enhancing mass measuring 3x3.6x2.3 cm in the right and 4.0x4.7x3.5cm in the left	(CT scan) Multilocular left adnexal cystic mass (9.7x10.4x8.0cm) with enhancing solid component possibly presenting an ovarian new growth	(UTZ) Right adnexal mass likely ovarian in etiology, irregularly shaped mass measuring 4.4x3.7x3.2cm in the right adnexa
Preoperative Tumor Markers	CA 125: 1090 U/ml	CA 125: 140 U/ml	CA 125: 500U/ml	CA 125: 480.80 U/ml
Surgical management	Exploratory laparotomy, Peritoneal fluid cytology, total hysterectomy with bilateral salpingoophorectomy; with omentectomy and lymphadenectomy			
Final Diagnosis	Primary High Grade Serous Carcinoma, Fallopian Tube, Stage IVB	Primary High Grade Serous Carcinoma, Fallopian Tube, Stage IIIA2	Primary High Grade Serous Carcinoma, Fallopian Tube, Stage IIIC	Primary High Grade Serous Carcinoma, Fallopian Tube, Stage IIIC
Adjuvant Treatment	Chemotherapy with Carboplatin-Paclitaxel x 6 cycles s/p Pegylated Doxorubicin x 4 cycles (ongoing treatment)	None	Oral Capecitabine x 9 months	None
Status	Alive (17 months from diagnosis)	Alive (40 months from diagnosis)	Expired (12 months from diagnosis)	Expired (2 months from diagnosis)

APPENDIX B. CASE 1

Figure 1.1 Gross

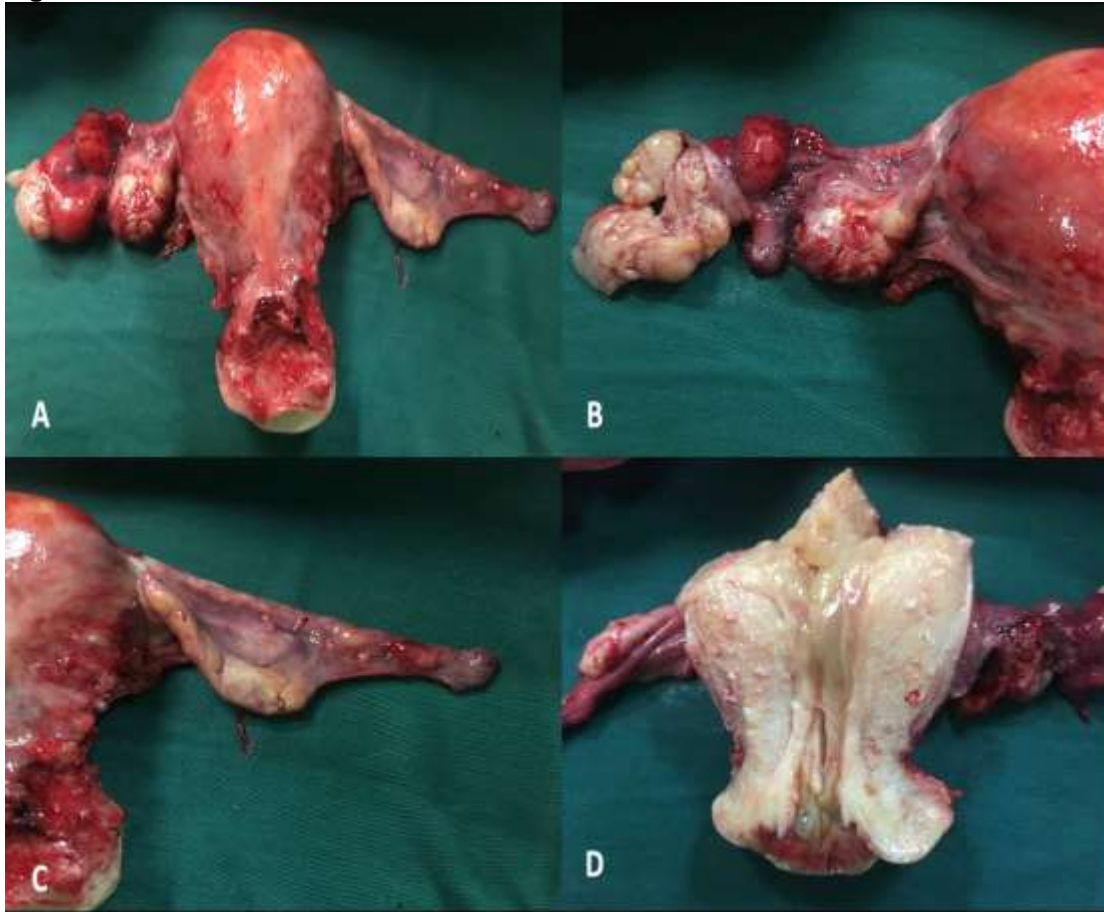

Figure 1.1.

1.1.A: A grossly abnormal left adnexa with a normal uterus and right fallopian tube and ovary

1.1.B: A close up on the left fallopian tube which was thinned out and dilated to 5.0x2.8x0.6 cm, f with granular fleshy tissue at the distal 3rd measuring 3.8x3.5x3.0

1.1.C: The right fallopian tube and ovary which is grossly normal

1.1.D: Cut section of the uterus which is grossly normal

Figure 1.2. Microscopic

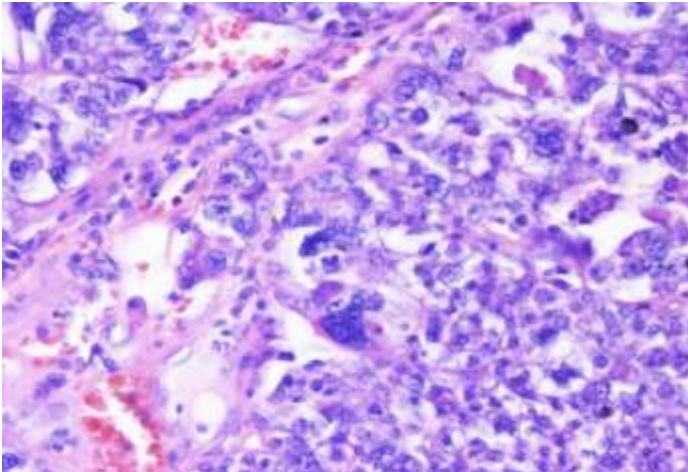


Figure 1.2.A: High power view stained by H&E of the main mass found at the left fallopian tube showing nuclear atypia showing prominent nucleoli and pleomorphism.

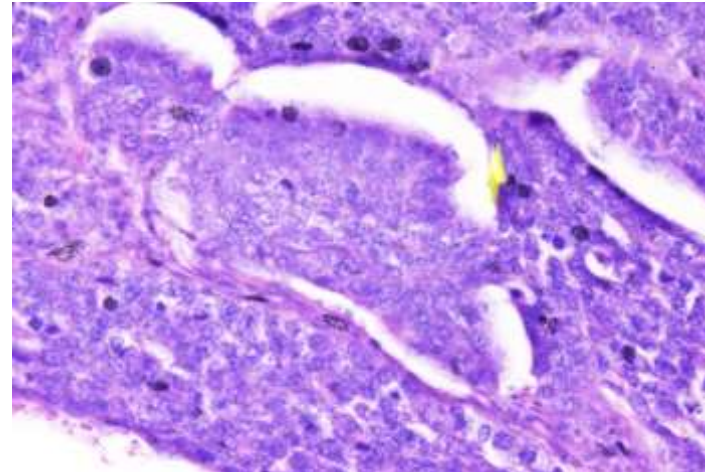


Figure 1.2.B: High power view stained by H&E of the main mass found at the left fallopian tube revealing lymphovascular invasion.

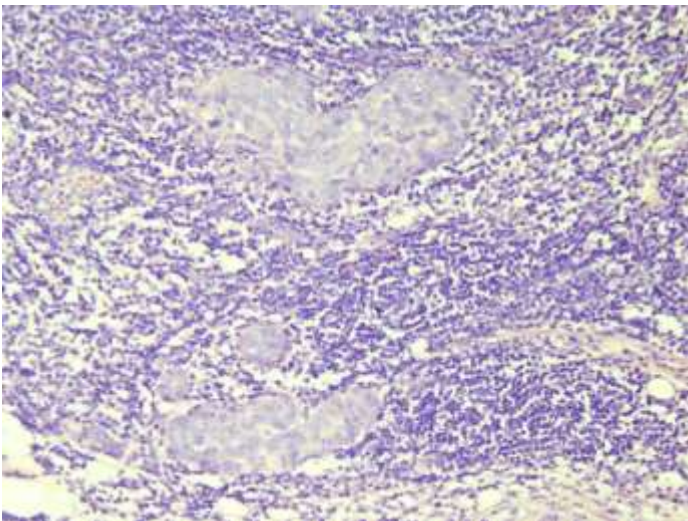


Figure 1.2.C: High power view stained by H&E of one of the lymph nodes showing tumor deposits.

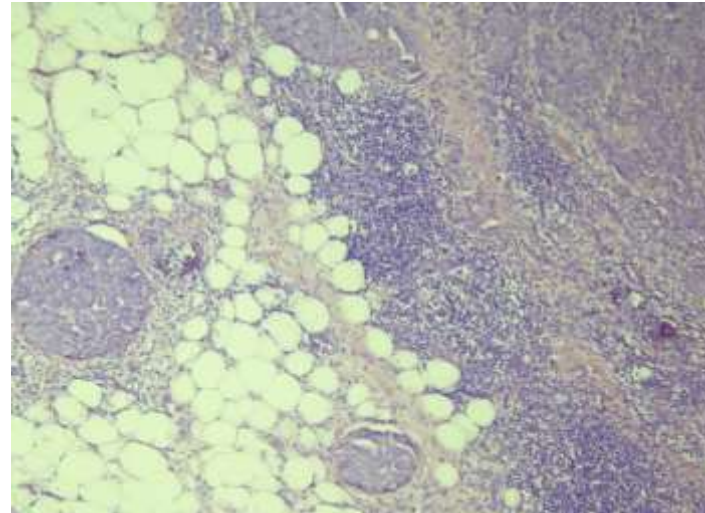


Figure 1.2.D: Low power view stained by H&E showing perinodal metastasis.

APPENDIX C. CASE 2

Figure 2.1. Gross

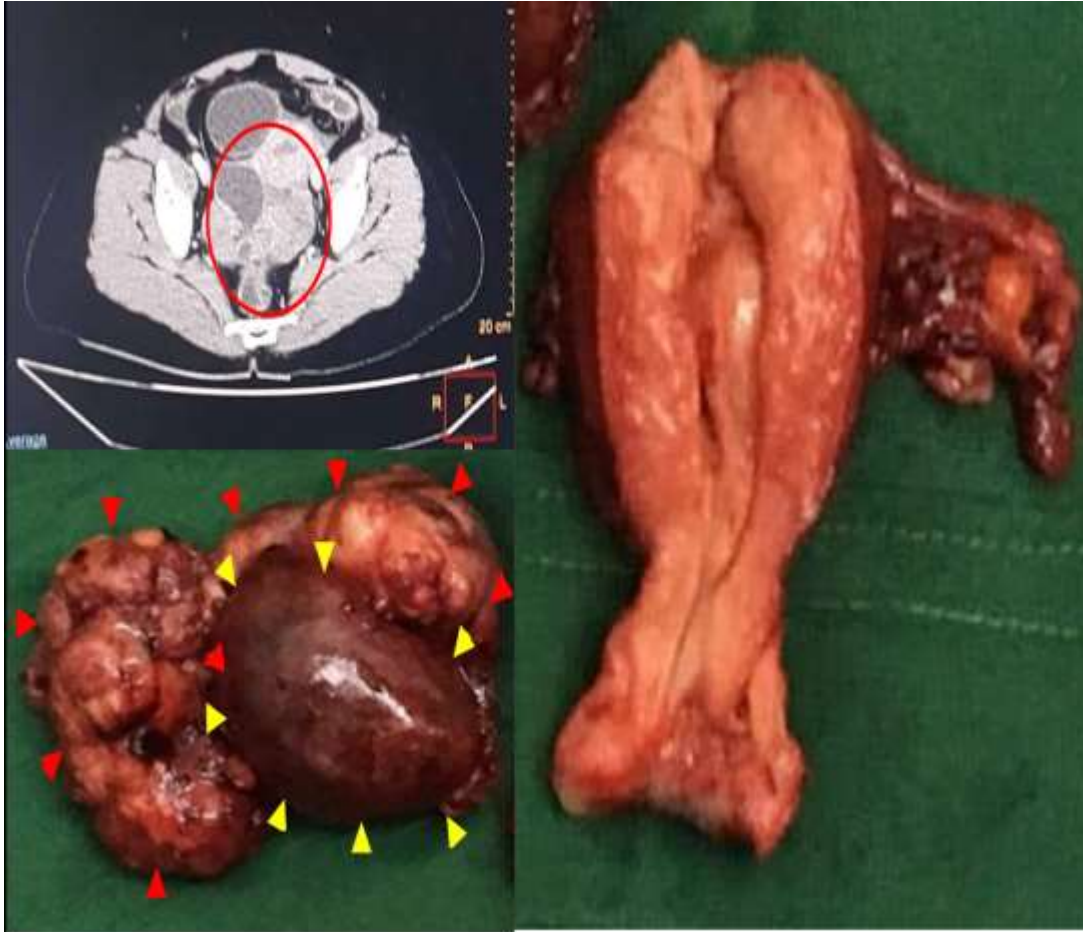


Figure 2.1.

2.1.A: The CT images reveal there are two solid, heterogeneously enhancing mass in the pelvic cavity measuring 3 x 3.6 x 2.3 cm in the right 4.0 x 4.7 x 3.5 in the left respectively

2.1.B: Right ovary enlarged to 8 x 10 x 3 cm. containing chocolate fluid. (yellow arrowheads) Upon dissection, mass was multiloculated, containing chocolate fluid, no noted solid nor papillarities. The right fallopian tube cannot be grossly identified but an adnexal mass is noted at the area of the right fallopian tube measuring 10.5 x 7 x 4 cm with cream, purulent cut surfaces (red arrowheads).

2.1.C: Uterus with noted submucosal myoma, cervix, left fallopian tube and ovary that is grossly normal.

Figure 2.2. Microscopic

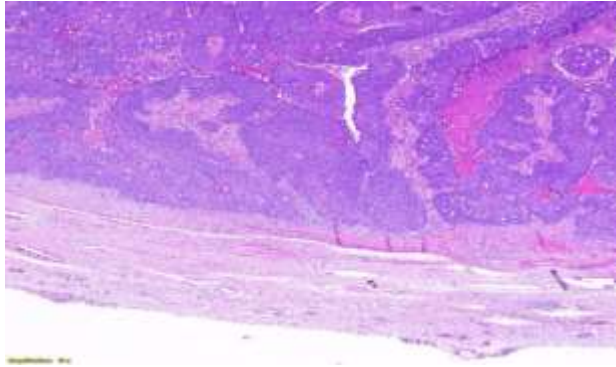


Figure 2.2.A: Low power view stained by H&E of the right fallopian tube revealing malignant cells arranged in sheets, with focal papillary and glandular formation and accompanying necrosis

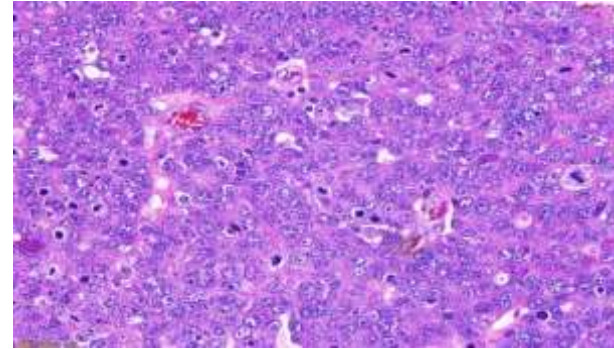


Figure 2.2.B: High power view stained by H&E of the main mass found at the right fallopian tube revealing enlarged, pleomorphic, hyperchromatic to vesicular nuclei, some with prominent nucleoli surrounded by scant eosinophilic, irregular to polyhedral cytoplasm. These are accompanied by frequent mitoses.

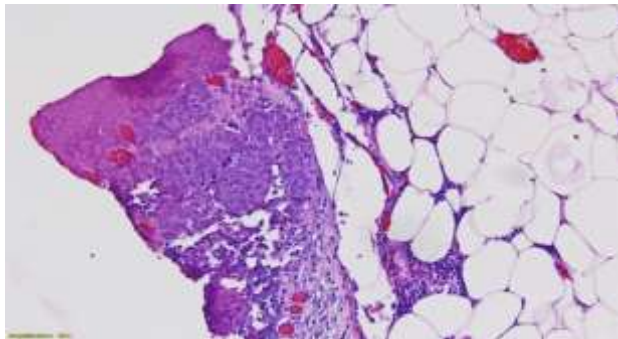


Figure 2.2.C: Omentum. This is a high power view stained by H&E of the omentum with sheets of atypical cells having enlarged, hyperchromatic nuclei, which appears to be similar to the main mass found in the fallopian tube.

Figure 3.1. Gross

APPENDIX D. CASE 3

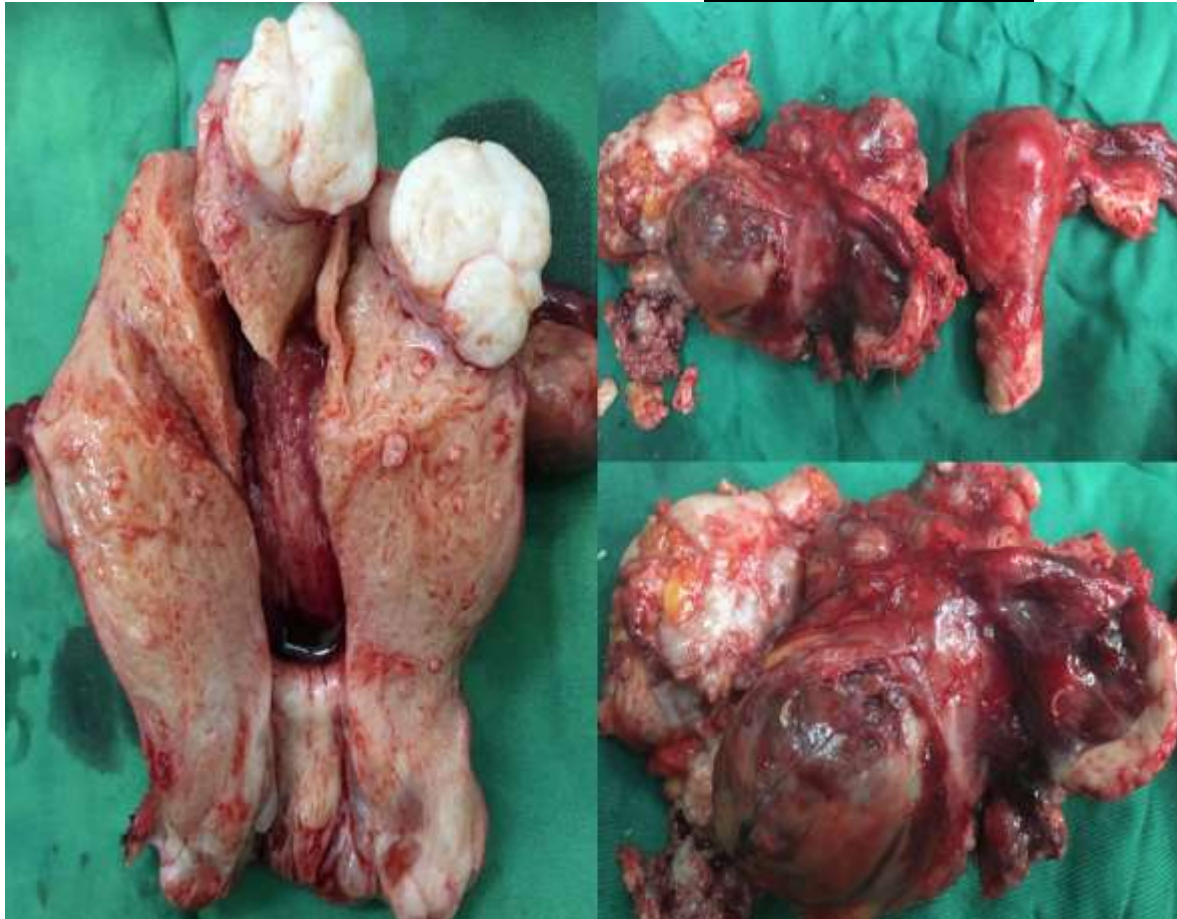


Figure 3.1.

3.1.A: Uterus with attached cervix, incised and opened from cervix to fundus. Myoma Uteri noted at the fundus.

3.1.B: A grossly abnormal left adnexa with a normal uterus and right fallopian tube and ovary

3.1.C: A close up on the left fallopian tube that was converted to a 20x25cm multiloculate mass with friable tissue within. The left ovary was grossly unremarkable.

Figure 3.2. Microscopic

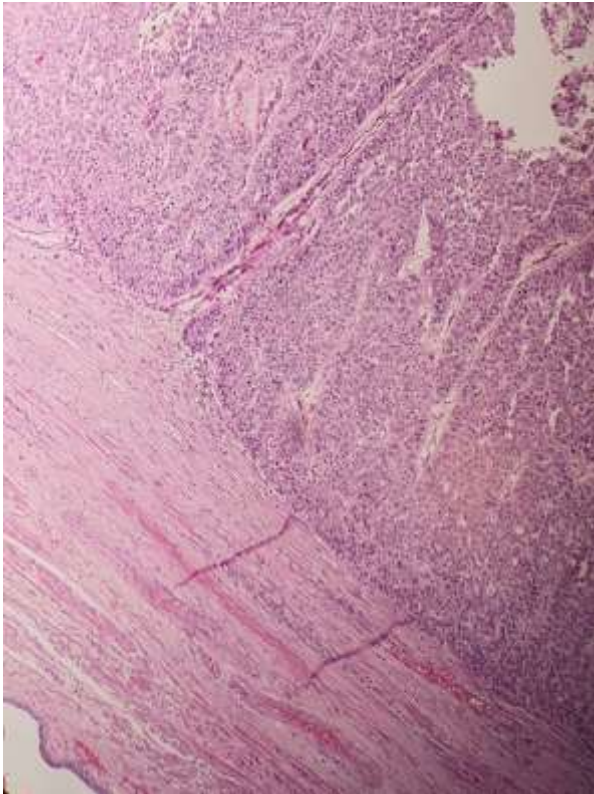


Figure 3.2.A: Low power view stained by H&E of the left fallopian tube revealing malignant cells arranged in sheets, with focal papillary and glandular formation.

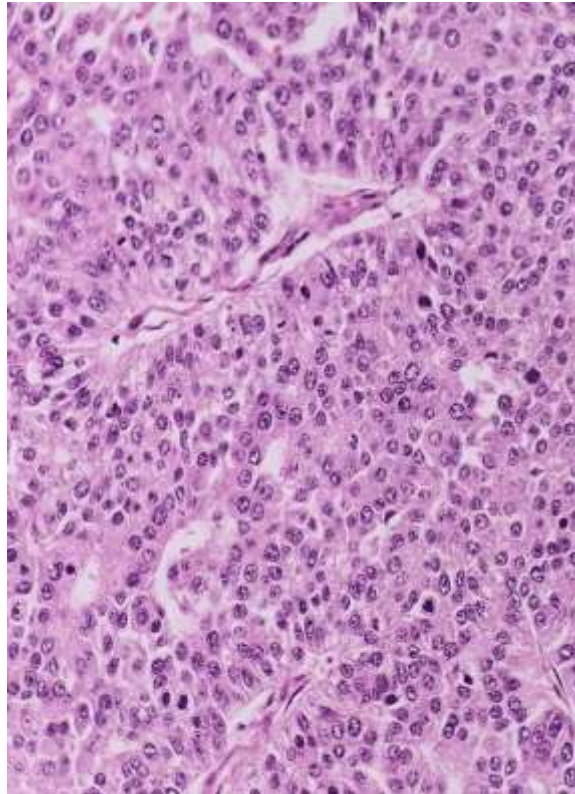


Figure 3.2.B: High power view stained by H&E of the main mass found at the left fallopian tube revealing enlarged, pleomorphic, hyperchromatic to vesicular nuclei, some with prominent nucleoli surrounded by scant eosinophilic, irregular to polyhedral cytoplasm. These are accompanied by frequent mitoses.

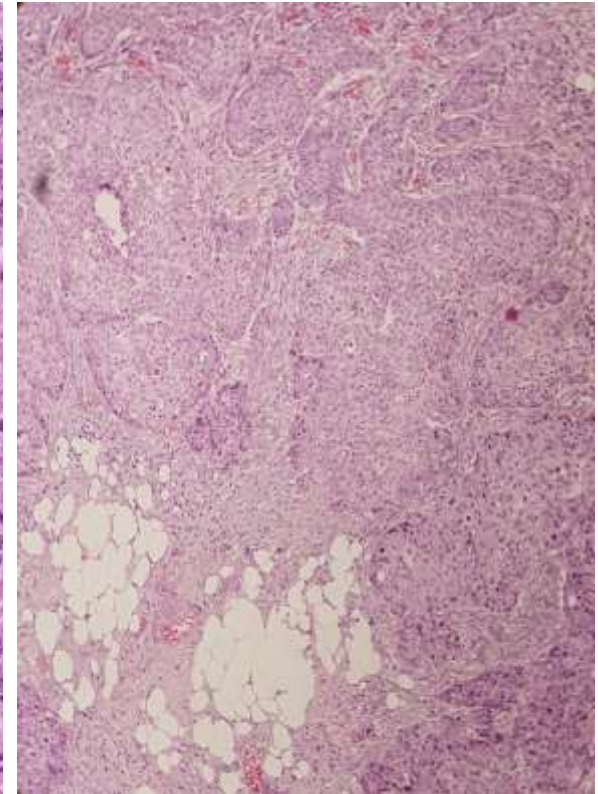


Figure 3.2.C: Omental Tumor Nodule. This is a low power view stained by H&E of the omentum with sheets of atypical cells having enlarged, hyperchromatic nuclei, which appears to be similar to the main mass found in the fallopian tube.

APPENDIX E. CASE 4

Figure 4.1. Gross

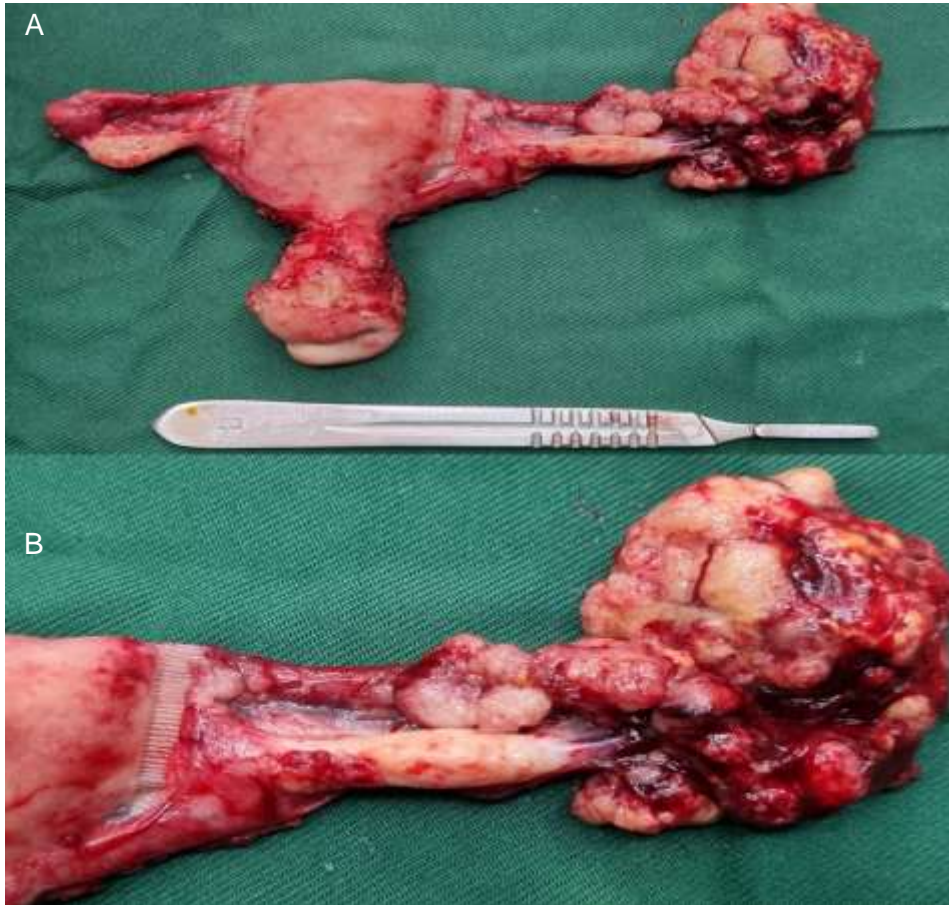


Figure 4.1.

4.1.A: A grossly abnormal right adnexa with a normal uterus and left fallopian tube and ovary

4.1.B: The left fallopian tube was converted to a 6x6 friable mass

Figure 4.2. Microscopic

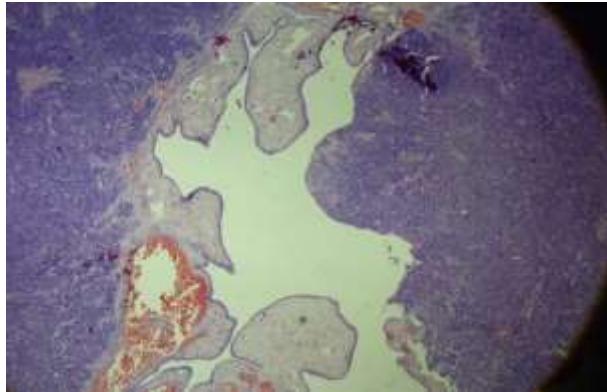


Figure 4.2.A: Low power view stained by H&E of the left fallopian tube showing normal histology that is surrounded by high grade serous carcinoma.

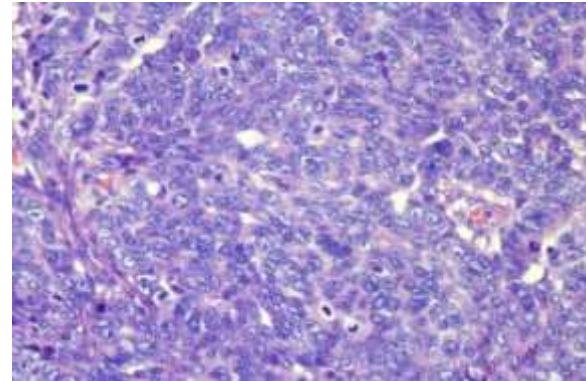


Figure 4.2.B: High power view stained by H&E of the main mass found at the left fallopian tube revealing enlarged, pleomorphic, hyperchromatic nuclei, some with prominent nucleoli surrounded by scant eosinophilic, irregular cytoplasm. These are accompanied by frequent mitoses.

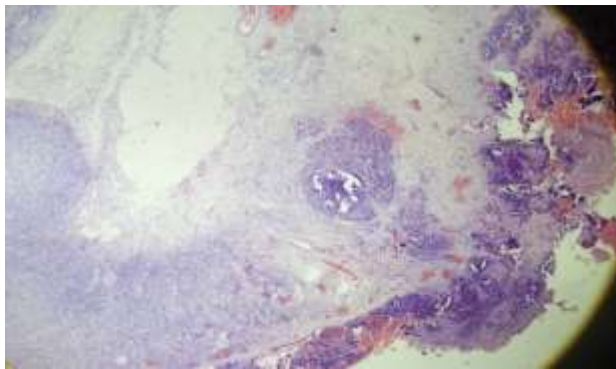


Figure 4.2.C: Low power view stained by H&E showing the tumor extending to the ovarian surface.

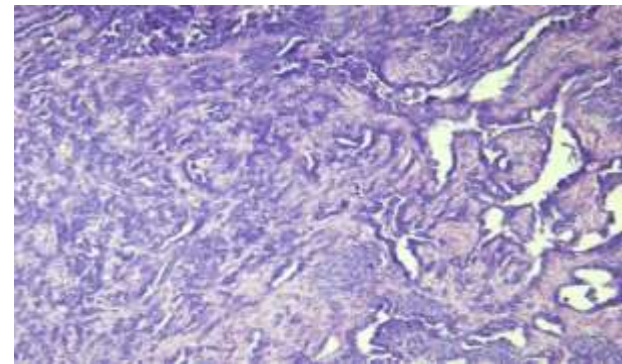


Figure 4.2.D: Omentum and Peritoneum. This is a high power view stained by H&E of the omentum and peritoneum with sheets of atypical cells having enlarged, hyperchromatic nuclei, which appears to be similar to the main mass found in the fallopian tube.

APPENDIX F: FIGO 2014 CLASSIFICATION

I	Tumor confined to ovaries or fallopian tube(s)	T1
IA	Tumor limited to one ovary (capsule intact) or fallopian tube, No tumor on ovarian or fallopian tube surface No malignant cells in the ascites or peritoneal washings	T1a
IB	Tumor limited to both ovaries (capsules intact) or fallopian tubes No tumor on ovarian or fallopian tube surface No malignant cells in the ascites or peritoneal washings	T1b
IC	Tumor limited to one or both ovaries or fallopian tubes, with any of the following: IC1 Surgical spill intraoperatively IC2 Capsule ruptured before surgery or tumor on ovarian or fallopian tube surface IC3 Malignant cells present in the ascites or peritoneal washings	T1c
II	Tumor involves one or both ovaries or fallopian tubes with pelvic extension (below pelvic brim) or peritoneal cancer (Tp)	T2
IIA	Extension and/or implants on the uterus and/or fallopian tubes/and/or ovaries	T2a
IIB	Extension to other pelvic intraperitoneal tissues	T2b
III	Tumor involves one or both ovaries, or fallopian tubes, or primary peritoneal cancer, with cytologically or histologically confirmed spread to the peritoneum outside the pelvis and/or metastasis to the retroperitoneal lymph nodes	T3
IIIA	Metastasis to the retroperitoneal lymph nodes with or without microscopic peritoneal involvement beyond the pelvis	T1,T2,T3aN1
IIIA1	Positive retroperitoneal lymph nodes only (cytologically or histologically proven)	
IIIA1(i)	Metastasis ≤ 10 mm in greatest dimension (note this is tumor dimension and not lymph node dimension)	T3a/T3aN1
IIIA1(ii)	Metastasis > 10 mm in greatest dimension	
IIIA 2	Microscopic extrapelvic (above the pelvic brim) peritoneal involvement with or without positive retroperitoneal lymph nodes	T3a/T3aN1
IIIB	Macroscopic peritoneal metastases beyond the pelvic brim ≤ 2 cm in greatest dimension, with or without metastasis to the retroperitoneal lymph nodes	T3b/T3bN1
III C	Macroscopic peritoneal metastases beyond the pelvic brim > 2 cm in greatest dimension, with or without metastases to the retroperitoneal nodes (Note 1)	T3c/T3cN1
IV	Distant metastasis excluding peritoneal metastases Stage IV A: Pleural effusion with positive cytology Stage IV B: Metastases to extra-abdominal organs (including inguinal lymph nodes and lymph nodes outside of abdominal cavity) (Note 2) (Note 1: includes extension of tumor to capsule of liver and spleen without parenchymal involvement of either organ) (Note 2: Parenchymal metastases are Stage IV B)	Any T, Any N, M1 T3c/T3cN1

Notes:

1. Includes extension of tumor to capsule of liver and spleen without parenchymal involvement of either organ.
2. Parenchymal metastases are Stage IV B.