

# Primary Leiomyosarcoma of the Ovary: A Case Report of a Rare Ovarian Malignancy

Dixie Jane Bangasan, Jimmy Billod

Department of Obstetrics and Gynecology, Baguio General Hospital and Medical Center, Philippines.

## Abstract

Primary leiomyosarcoma of the ovary is a sporadic ovarian tumor constituting less than 0.1% of ovarian malignancies. This ovarian tumor is noted to have a very poor prognosis and generally affects post-menopausal women with few exceptions involving cases seen in younger women, as in the index case. Due to its rarity, there are no large series of case reports in the literature, and definitive treatment guidelines have not yet been developed. This report presents a reproductive woman with primary ovarian leiomyosarcoma who underwent exploratory laparotomy and total hysterectomy with bilateral salpingo-oophorectomy, received adjuvant chemotherapy postoperatively and later underwent tumor debulking post chemotherapy.

**Keywords:** leiomyosarcoma of the ovary- malignancy- rare ovarian cancer

*Asian Pac J Cancer Care*, 10 (3), 993-997

Submission Date: 03/01/2025

Acceptance Date: 05/19/2025

## Introduction

Primary leiomyosarcoma of the ovary (POLMS) is a very rare tumor constituting less than 0.1% of all ovarian malignancies. As of September 2022, there has been a total of 113 published cases of POLMS [1], 2 of which are reported to be in the Philippines [2, 3], making this the 3rd case in the country to be documented. This ovarian tumor generally affects postmenopausal women with a few exceptions involving cases seen in younger women, as in the index case. POLMS typically presents with non-specific symptoms. Diagnosis is made through histopathologic and immunohistochemical analysis. Studies have suggested that the disease prognosis is poor with only a 20% 5-year survival rate [4], with tumor stage, size, and mitotic index being the common prognostic factors [5]. Due to its rarity, definitive treatment guidelines have not yet been developed. This article presents a reproductive woman with primary ovarian leiomyosarcoma and reviews the recent literature.

### Case Protocol

A 41-year-old, G1P1(1001) came in with a 2-year history of intermittent left lower quadrant pain with no associated vaginal bleeding nor bladder or bowel movement changes. She has no known comorbidities and

no previous gynecological illnesses.

One month before admission, the patient consulted due to persistent abdominal pain. Pelvic ultrasonography showed a large solid lobulated mass with some cystic changes measuring 15.0 x 10.0 x 11.3 cm (Figure 1). She was advised of surgery but was lost to follow-up. In the same month, the patient then sought consult for a palpable abdominal mass with no associated remarkable signs and symptoms. Another pelvic ultrasonography revealed an irregular heterogeneous solid mass measuring 17.5 x 10.8 x 9.2 cm with 81.1% risk of malignancy by IOTA Adnex and multiple myoma uteri, CA-125 level was high at 191.77U/ml. Physical examination of the abdomen revealed a palpable abdominopelvic mass measuring 18 x 20 cm, irregular, solid, slightly tender, with limited mobility. The external genitalia was normal, the vagina smooth, the cervix smooth with no masses, and the pelvoabdominal mass was noted to be extending down the posterior cul-de-sac.

The patient underwent exploratory laparotomy. Intraoperative findings revealed that the left ovary and fallopian tube were transformed into a large irregular nodular mass, 18 x 12 x 10 cm, adherent to the pelvis side walls and cul de sac. Adhesiolysis was done

### Corresponding Author:

Dr. Dixie Jane Bangasan

Department of Obstetrics and Gynecology, Baguio General Hospital and Medical Center, Philippines.

Email: dixiebangasan@gmail.com

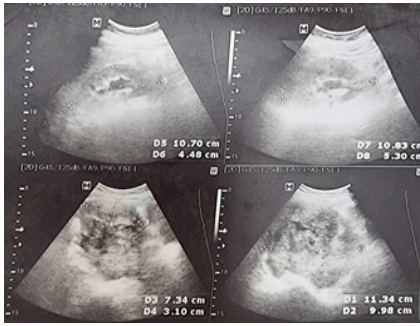


Figure 1. Ultrasound. A large solid lobulated mass with some cystic changes at the presacral area measuring 15.0 x 10.0 x 11.3 cm pushing the uterus anteriorly and superiorly

followed by left salpingo-oophorectomy. Cut section of the mass revealed a cream-solid surface with areas of hemorrhage (Figure 2). The uterus was noted to have intramural leiomyomas and the contralateral adnexa was unremarkable (Figure 2). A total hysterectomy with right salpingo-oophorectomy was then performed followed by an assessment of lymph nodes and other abdominal organs. No enlarged lymph nodes or other tumor masses were noted. The plan was to do a complete surgical staging including bilateral pelvic lymph node dissection, infracolic omentectomy, and random peritoneal biopsy. However, an earthquake suddenly occurred and the procedure had to be cut short due to the emergency situation.

The initial histopathologic diagnosis was primary leiomyosarcoma versus fibrosarcoma of the left ovary (Figure 3). Immunohistochemistry of the tissue revealed positivity for vimentin, smooth muscle actin, and desmin and negative for CD34 (Figure 4). With the given histopathologic and immunohistochemistry results, a final diagnosis of leiomyosarcoma of the ovary was made. Other submitted organs were negative for malignancy.

Repeat CA125 after resection of the mass is 7.0 IU/ml. Selection of chemotherapy agents were based on the current recommendations for primary uterine leiomyosarcoma. The patient underwent 6 cycles of adjuvant chemotherapy with single agent Doxorubicin, which was tolerated well. On post-chemotherapy surveillance after 6 cycles of Doxorubicin, she had no subjective complaints such as abdominal pain or changes in bladder or bowel habits. A whole abdominal CT scan was done showing fairly defined isodense soft tissue masses in the pelvic region approximately measuring 4.4 x 6.8 x 8.3 cm and 2.5 x 1.8 x 3.2cm (Figure 5a). The mass demonstrates peripheral enhancement with central areas of necrosis. The imaging suggests tumor recurrence.

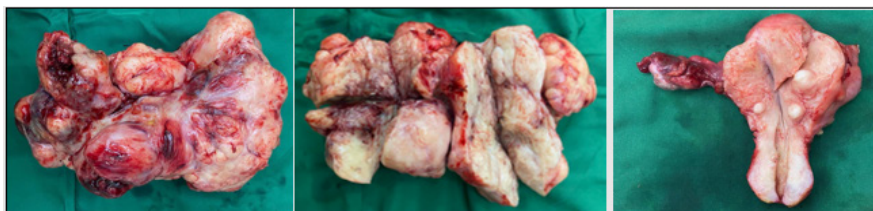


Figure 2. Gross Specimen. Left ovary and fallopian tube is transformed into a large irregular nodular mass with cream fibromyxoid cut surfaces and areas of hemorrhage. Uterus with intramural leiomyomas and grossly normal-looking contralateral adnexa.

She received 2nd line chemotherapy with Gemcitabine-Docetaxel. After 6 cycles, a repeat CT scan showed regression in the size of the well-defined isodense structure, now measuring 3.6 x 4.9 x 4.3 cm, and a minimal increase in the size of a similar-looking lesion to 2.8 x 4.7 x 3.7 cm. A repeat CT scan after 9 cycles of Gemcitabine-Docetaxel showed minimal progression in the size of the isodense structures to 4.3 x 3.9 x 4.5 cm and 3.8 x 3.6 x 4.7cm (Figure 5b), which by Response Evaluation Criteria in Solid Tumor (RECIST) classifies the patient under stable disease. Internal examination revealed a smooth vagina with intact stump, and an irregular, solid mass measuring 3 x 4 cm, movable, non-tender on the right pelvic area.

The patient then underwent exploratory laparotomy, enterolysis and tumor debulking for the tumor recurrence followed by omental biopsy and bilateral pelvic lymph node assessment. Intraoperative findings showed bilateral solid pelvic masses measuring 6 x 6 x 8 cm at the right, and 6 x 6 x 5 at the left. The bilateral pelvic masses were adherent to the sigmoid colon, the posterior cul-de-sac and pelvic side walls. A 2 x 2 cm solid mass remained plastered to the posterior cul-de-sac and rectal serosa. On cut section, both masses revealed smooth white whorled surfaces with areas of hemorrhage (Figures 6). Histopathologic diagnosis of the mass revealed malignant spindle cell tumor consistent with leiomyosarcoma. Post-operatively, the patient received an additional 4 cycles of Dacarbazine before succumbing 24 months after initial diagnosis.

#### Case Discussion

Primary leiomyosarcoma of the ovary is a very rare oncological pathology accounting for less than 0.1% of all ovarian malignancies [2, 4, 6]. As of September 2022, there has been a total of 113 published cases of POLMS [1], 2 of which are reported to be in the Philippines [2, 3], making this the 3rd case in the country to be documented.

Since the ovary does not contain smooth muscle cells, the pathogenesis of POLMS is still unclear. Although it is proposed to originate from smooth muscle fibers of ovarian vessels or ligaments, remnants of the Wolffian duct, from the transformation of totipotent ovarian mesenchymal cells or smooth muscle metaplasia of ovarian stromal or theca cells or smooth muscle cells [1]. POLMS can also represent a malignant degeneration of a benign ovarian leiomyoma or can arise within a benign cyst such as teratoma, serous cystadenoma or in papillary serous cystadenocarcinoma [1].

POLMS typically affects post-menopausal women,

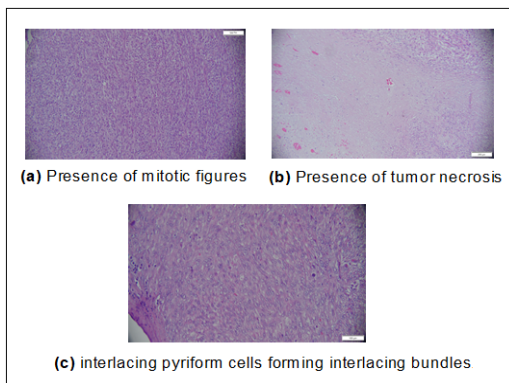


Figure 3. Histopathologic Assessment.

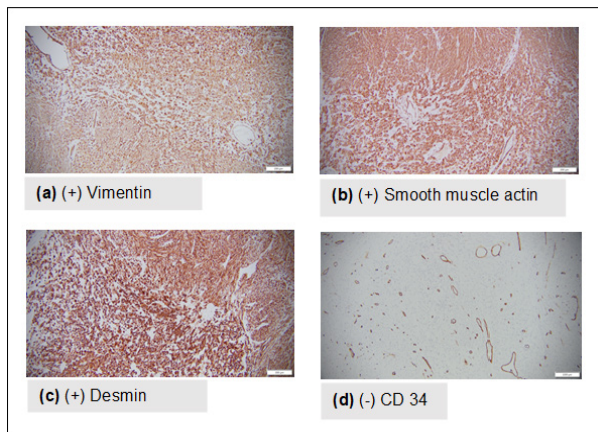


Figure 4. Immunohistochemical Assessment.

with a mean age of occurrence at 53 years old, but cases also occur in younger women, with the youngest documented case at 12 years old [1]. It is generally unilateral with rapid disease progression presenting with non-specific symptoms, such as abdominal pain, abdominal distention, weight loss, and altered urinary and bladder habits, most of which present in advanced stages of the disease. Tumor markers such as CA125, CEA, and CA19-9 are usually normal or only slightly elevated.

Preoperative diagnosis of POLMS is difficult due to non-specific symptoms and ambiguous imaging findings, showing both benign and malignant features. Grossly, these tumors are characterized to be of variable size, lobular, solid, and fleshy, with areas of necrosis and hemorrhage, which is similar to the specimens of the index case. Histologically, it is indistinguishable from uterine leiomyosarcomas, with the presence of eosinophilic spindle-shaped cells with enlarged, variably pleomorphic nuclei arranged in intersecting fascicles or sheets [4]. Thus, a diagnosis of primary ovarian leiomyosarcoma is made if two out of the three diagnostic criteria is fulfilled: (1) coagulative necrosis, (2) cellular atypia, and (3) mitotic index  $> 10$  per high power field. However, primary ovarian leiomyosarcoma may also be diagnosed when the mitotic index is  $< 10$  per HPF with absence of necrosis but with pronounced atypia [1, 5, 7].

Immunohistochemistry is helpful to distinguish a leiomyosarcoma of the ovary from other ovarian sarcomas, such as fibrosarcoma. Based on a systematic review of 113 cases of POLMS, smooth muscle actin is positive in

94.6% of patients, vimentin in 100%, desmin in 85.7% and CD34 in 15.4% [1]. In comparison, a metaanalysis on ovarian fibrosarcoma, although involving only 31 patients, showed that ovarian fibrosarcoma is positive for smooth muscle actin in only 11% of patients, vimentin in 100%, desmin in 8% and CD34 in 20% [8]. Further testing with h-caldesmon can be done to distinguish POLMS from fibrosarcoma, since it is negative in patients with ovarian fibrosarcoma and positive for patients with POLMS although only for those of vascular origin.

The staging of ovarian leiomyosarcomas follows the FIGO classification for epithelial ovarian tumors. Although a complete staging procedure was not possible in this case, it was staged as IIB due to the presence of pelvic adhesions.

Due to its rarity, no recommended guidelines on optimal treatment of POLMS have been established. The Gynecologic Cancer InterGroup (GCIg) Consensus recommends total hysterectomy and bilateral salpingo-oophorectomy as the initial surgical approach. It further states that for patients who have not had lymph node dissection or omentectomy, a second operation is not considered necessary since the probability of occult metastatic disease is likely low [9]. However, recent studies documented the efficacy of lymphadenectomy in improving the prognosis, disease-free, and overall survival of primary ovarian leiomyosarcoma patients [1, 10]. In the study of Mandato et. al, patients who underwent surgery with lymph node dissection plus chemotherapy had 100% survival at 120 months compared to patients who underwent surgery without lymph node dissection plus chemotherapy who had a median overall survival of 24 months ( $p=0.0045$ ). In our index case, the earthquake has limited the surgeon from performing a lymph node dissection that could have been beneficial in improving the patient's survival rate.

The GCIg consensus also states that there are no prospective data to support the routine use of adjuvant chemotherapy in diseases limited to the ovary. For locally advanced, completely resected disease, postresection chemotherapy with agents used for uterine leiomyosarcoma may be considered, however, there are no data to show that treatment improves survival outcomes [9]. Reported cases that have undergone chemotherapy have used regimens that include doxorubicin +/- ifosfamide, gemcitabine

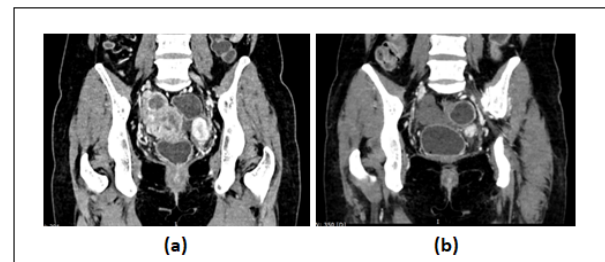


Figure 5. Abdominal CT Scan. (a) A fairly defined isodense soft tissue mass in the pelvic region approximately measuring 4.4 x 6.8 x 8.3 cm and 2.5 x. (b) A fairly defined isodense soft tissue mass in the pelvic region approximately measuring 4.4 x 6.8 x 8.3 cm and 2.5 x



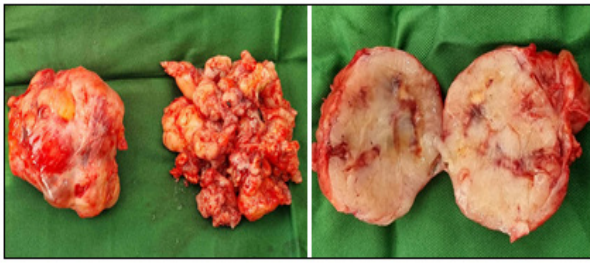


Figure 6. Bilateral Solid Pelvic Masses Measuring 6 x 6 x 8cm at the Right and 6 x 6 x 5 cm at the Left. On cut section, both masses revealed smooth white whorled surface with areas of hemorrhage

+/- docetaxel, pazopanib, trabectedin, dacarbazine, and temozolomide [4, 9]. Although response rates of second-line chemotherapy on soft tissue sarcomas are usually low, absence of disease progression could still be a meaningful clinical achievement [8]. The pelvis is the most common site of recurrence of POLMS (46.9%), followed by the upper abdomen (28.1%) and the thorax (25.0%) [1]. Our patient in this case underwent 6 cycles of Doxorubicin and noted recurrence in the pelvis 3 months after treatment, however achieved stable disease after 9 cycles of Gemcitabine-Docetaxel.

The role of radiotherapy for POLMS has not been established [1]. Postoperative radiotherapy may be effective in local control of the disease but does not prevent the development of distant metastases. Targeted therapy and immunotherapy have been studied in cases of uterine leiomyosarcoma [11], however, the role of such treatments for POLMS has not been adequately investigated. Hormonal blockade in uterine leiomyosarcomas has also been studied and may also be considered for patients with low disease burden and indolent disease pace [11].

Studies suggest that the prognosis of POLMS is poor, with a mean disease-free survival reported to be 12.5 months and only a 20% 5-year survival rate [4]. Stage and mitotic index are the most common prognostic factors of the disease. Tumor stage was noted to be a principal factor affecting survival, as patients with early-stage (I-II) showed better overall survival than patients with advanced stages (III-IV) with a median overall survival of 54 vs 18 months respectively [5, 10]. Mitotic count may also affect prognosis as patients with mitotic count >10 per hpf had a median survival of 35 months compared to those with a lower number of mitosis with a median survival of 63 months.

## Acknowledgments

### Statement of Transparency and Principals

- Author declares no conflict of interest
- Study was approved by Research Ethic Committee of author affiliated Institute.
- Study's data is available upon a reasonable request.
- All authors have contributed to implementation of this research.

## References

1. Mandato VD, Torricelli F, Mastrofilippo V, Palicelli A, Costagliola L, Aguzzoli L. Primary Ovarian Leiomyosarcoma Is a Very Rare Entity: A Narrative Review of the Literature. *Cancers*. 2023 05 28;15(11):2953. <https://doi.org/10.3390/cancers15112953>
2. Uy SA, Galbo PE. Primary ovarian leiomyosarcoma in a 72-year-old nulligravid and the 2022 provisional diagnostic criteria for primary ovarian leiomyosarcoma. *Philippine Journal of Obstetrics and Gynecology*. 2022 Dec;46(6):271. [https://doi.org/10.4103/pjog.pjog\\_50\\_22](https://doi.org/10.4103/pjog.pjog_50_22)
3. Decipulo DAA, Bagadiiong JG. Primary ovarian leiomyosarcoma in a postmenopausal woman diagnosed using immunohistochemistry. *Philippine Journal of Obstetrics and Gynecology*. 2022 Oct;46(5):224. [https://doi.org/10.4103/pjog.pjog\\_41\\_22](https://doi.org/10.4103/pjog.pjog_41_22)
4. Cojocar E, Palahepitiva Gamage G, Butler J, Barton DP, Thway K, Fisher C, Messiou C, et al. Clinical management and outcomes of primary ovarian leiomyosarcoma - Experience from a sarcoma specialist unit. *Gynecologic Oncology Reports*. 2021 05;36:100737. <https://doi.org/10.1016/j.gore.2021.100737>
5. Taşkin S, Taşkin EA, Uzüm N, Ataoğlu O, Ortaç F. Primary ovarian leiomyosarcoma: a review of the clinical and immunohistochemical features of the rare tumor. *Obstetrical & Gynecological Survey*. 2007 07;62(7):480-486. <https://doi.org/10.1097/01.ogx.0000268629.16151.71>
6. Zhang Q, Wang K, Wang B. Primary ovarian leiomyosarcoma: a case report. *The Journal of International Medical Research*. 2024 09 17;52(9):03000605241276807. <https://doi.org/10.1177/03000605241276807>
7. Lerwill MF, Sung R, Oliva E, Prat J, Young RH. Smooth muscle tumors of the ovary: a clinicopathologic study of 54 cases emphasizing prognostic criteria, histologic variants, and differential diagnosis. *The American Journal of Surgical Pathology*. 2004 Nov;28(11):1436-1451. <https://doi.org/10.1097/01.pas.0000141393.99300.d0>
8. Huang L, Liao L, Wang H, Zheng M. Clinicopathologic characteristics and prognostic factors of ovarian fibrosarcoma: the results of a multi-center retrospective study. *BMC cancer*. 2010 Oct 27;10:585. <https://doi.org/10.1186/1471-2407-10-585>
9. Hensley ML, Barrette BA, Baumann K, Gaffney D, Hamilton AL, Kim J, Maenpaa JU, et al. Gynecologic Cancer InterGroup (GCIg) consensus review: uterine and ovarian leiomyosarcomas. *International Journal of Gynecological Cancer: Official Journal of the International Gynecological Cancer Society*. 2014 Nov;24(9 Suppl 3):S61-66. <https://doi.org/10.1097/IGC.0000000000000261>
10. Yuksel D, Cakir C, Kilic C, Karalok A, Kimyon G, Çötelci S, Boyraz G, Tekin ÖM, Turan T. Primary leiomyosarcoma of the ovary: a report of three cases and a systematic review of literature. *Journal of Gynecology Obstetrics and Human Reproduction*. 2021 06;50(6):101825. <https://doi.org/10.1016/j.jogoh.2020.101825>
11. García-Del-Muro X, López-Pousa A, Maurel J, Martín J, Martínez-Trufero J, Casado A, Gómez-España A, et al. Randomized phase II study comparing gemcitabine plus dacarbazine versus dacarbazine alone in patients with previously treated soft tissue sarcoma: a Spanish Group for Research on Sarcomas study. *Journal of Clinical Oncology: Official Journal of the American Society of Clinical Oncology*. 2011 06 20;29(18):2528-2533. <https://doi.org/10.1200/JCO.2010.33.6107>



This work is licensed under a Creative Commons Attribution-Non Commercial 4.0 International License.