

# CT and MRI Based Gross Tumor Volume Comparison in Pharyngeal and Laryngeal Carcinoma

Vinin.N.V, Joneetha Jones, Aswanth.K.Anil, Akhil. P.Suresh, Satheesh Babu. T.V, Geetha Muttath, Arun Kumar. E.S

Department of Radiation Oncology, Malabar Cancer Centre, Thalassery, Kerala, India.

## Abstract

**Background:** Different other imaging modalities help in accurate gross tumor volume delineation. Studies have shown conflicting results for intermodality GTV comparison. Since in our institute we routinely take planning CT and planning MRI for laryngeal and pharyngeal tumors treated with definitive radiotherapy, with this study we intent to compare the gross tumor volume (GTV) with these modalities in these tumors. **Materials & Methods:** Study population included pharyngeal and laryngeal carcinoma patients treated. Planning CT and planning MRI images of these patients were retrieved. Gross tumor volume (GTV) was delineated by a Radiation Oncologist in both these image sets and GTVs were documented. **Results:** Out of 87 patients analysed, the overall median GTV with planning CT and planning MRI were 20.4 cc & 18.2 cc respectively. Median GTV with planning CT & MRI for different sites like Nasopharynx, Oropharynx, Larynx and Hypopharynx were 32.85 & 27.75 cc, 22.1 & 20.9 cc, 8.25 & 10.35cc and 20.55 & 20.6 cc respectively with no statistically significant difference. Median GTVs with CT & MRI for different primary tumor stages like T2, T3, T4a, T4b were 14.3 & 14.3 cc, 20.45 & 19 cc, 16.55 & 27.45 cc and 50.75 & 52.4 cc respectively. Analysis showed 94.6 % correlation between GTVs with CT & MRI. **Conclusion:** This study showed comparable median GTVs with planning CT & MRI for pharyngeal and laryngeal carcinomas. Subset analysis did not show any significant difference in GTVs with two modalities for different primary tumor site. As expected there was good correlation between GTVs of two modalities. Even though the results does not show significant intermodality variation for GTV delineation. With the results of this study we cannot question the use of multiple modalities for GTV delineation as subtle variation in GTV can result in differences in target volumes resulting in differences in toxicity profile.

**Keywords:** Gross tumor volume- Laryngeal and hypopharyngeal tumors- Planning CT- Planning MRI

*Asian Pac J Cancer Care*, 7 (1), 65-69

Submission Date: 01/26/2022 Acceptance Date: 03/01/2022

## Introduction

For conformal radiotherapy International Commission on Radiation Units and Measurements (ICRU) has defined different target volumes like gross tumor volume (GTV), clinical target volume (CTV) and planning target volume (PTV) [1]. In this era of conformal radiotherapy target volume delineation in head and neck cancers is a crucial step. Accurate target volume delineation is mandatory to avoid geographical misses leading to recurrences in view of steep dose gradients. Inaccuracy in tumor delineation is a well recognized error in radiotherapy treatment delivery. [2-4]. In conformal radiotherapy treatment delivery target

volume delineation remains a very subjective step. GTV delineation is affected by the type of imaging modality utilised [5]. CT based imaging is most commonly used for defining PTV. Latest treatment planning software allows registration of different imaging modalities with simulation CT images [6, 7]. In laryngeal tumors GTV delineation in CT scan has resulted in significant intra and interobserver variations [8]. Magnetic resonance imaging (MRI) more accurate than CT scan in head and neck tumors to evaluate soft tissue extension and bone invasion. [9]. However there are conflicting results on the utility of

### Corresponding Author:

Dr. Joneetha Jones

Associate Professor, Department of Radiation Oncology, Malabar Cancer Centre Thalassery, Kerala, India.

Emails: joneetha14@gmail.com, vininnair@gmail.com

multimodality imaging for GTV delineation in pharyngeal and laryngeal cancers [7, 10]. As an institutional practice we are doing planning MRI for pharyngeal and laryngeal carcinoma. Hence with this study we intended to assess the variation in GTV delineation with planning CT and MRI for pharyngeal and laryngeal carcinoma patients. We also aimed to assess the tumor site wise difference in variation in GTV delineation with CT and MRI.

## Materials and Methods

This was a retrospective study conducted in Radiation Oncology Department in a tertiary cancer centre from India.

### Inclusion Criteria

All pharyngeal and laryngeal carcinoma patients treated with Radical RT/ Chemoradiation during the period 1<sup>st</sup> January 2019 to 30<sup>th</sup> June 2019.

### Exclusion Criteria

Patients in whom planning MRI images are not available and patients in whom conformal radiotherapy was not used.

### Procedure

Case records of the selected patients was retrieved and the demographic details was documented. Planning CT and the co-registered MR images of already treated selected patients were retrieved. Radiation Oncologist delineated GTV in planning CT and planning MRI of each patient after a gap of at least one week, to avoid bias while contouring.

### Image Acquisition

#### Planning CT

Planning CT images were acquired in Wipro GE OPTIMA 580W 16 slice machine. Patients were immobilized with neck rest and thermoplastic shell. Intravenous contrast were given while taking planning CT. 2.5 mm slice thickness CT images of neck and thorax region were acquired.

#### Planning MRI

MRI images were acquired on 1.5 Tesla Signa HDtX machine. Patient were immobilized in same position and with the same thermoplastic mould which were used for planning CT. Axial T2 weighted (TR-6460, TE 112), FOV 26 × 26, Matrix 320 × 192, NEX-4 and axial STIR (TR-6940, TE- 49.8, T1-140), FOV-26 × 26, Matrix 320 × 160, NEX-2 sequences were acquired.

### Statistical analysis

Descriptive statistics like frequencies, percentages, median with interquartile range were used wherever appropriate. Mann-Whitney test was used for median comparison of GTVs. Pearson correlation test was used to find out the correlation between GTVs. Blant Altmann plot was used to plot mean GTV and average difference

between GTVs.

## Results

Total of 87 patient details were analysed. Median age of the patients were 62 years (Range 19-78). Majority were male patients 82 (94%). Among the study patients, the most common primary site was Oropharynx (52%) and site wise distribution of patients is shown in Table 1.

Patients were distributed among different tumor (T) as per TNM staging. The most common T stage was T3 (55%). Number of patients in different T stages like T1, T2, T3 and T4 were 1, 24, 48 and 14 respectively.

Median GTV in planning CT was 20.40 cc and it ranged from 1.1 to 85.8 cc. Median GTV in planning MRI was 18.20 and it ranged from 1.9-108.7 cc. Table 2 shows median GTVs in planning CT & MRI. Median comparison with Mann Whitney test did not show any statistically significant difference.

Pearson correlation showed a strong correlation between Planning CT & planning MRI GTVs. 94.9% correlation was observed which was statistically significant ( $p < 0.01$ ) and the scatter plot of the same is shown in Figure 1.

Primary sitewise GTVs in planning CT & MRI were analysed. Table 3 shows median GTVs in each site and median comparison between GTVs.

Pearson correlation between GTVs in each site is shown in Table 4, with all sites showing statistically

Table 1. Showing Primary Site Wise Distribution of Pharyngeal and Laryngeal Carcinoma Patients

Primary site	Frequency	Percent
Nasopharynx	4	4.6
Oropharynx	45	51.7
Larynx	24	27.6
Hypopharynx	14	16.1
Total	87	100

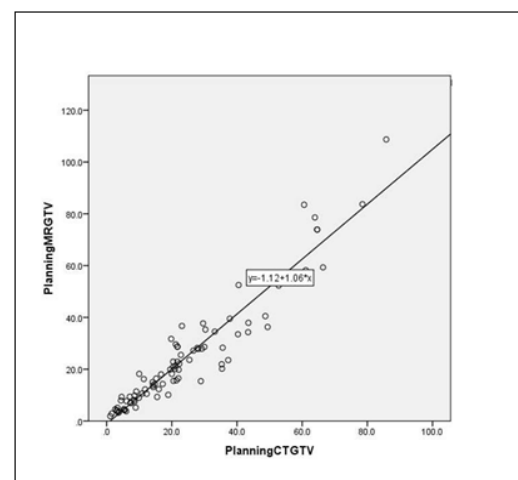


Figure 1. Scatter Plot Showing Correlation between Gross Tumor Volumes (GTVs) among Pharyngeal and Laryngeal Carcinoma Patients

Table 2. Showing the Gross Tumor Volumes (GTV) in Planning CT and Planning MRI among Pharyngeal and Laryngeal Carcinoma Patients

	Median GTV	Inter Quartile range (IQR)	No. of patients	P value
Planning CTGTV	20.4	8.90-30.30	87	
Planning MRGTV	18.2	9.30-29.60	87	0.544

Table 3. Showing Primary Sitewise GTV in Planning CT &amp; Planning MRI among Pharyngeal and Laryngeal Carcinoma Patients

Primarysite		Median	IQR	N	p value
Nasopharynx	Planning CT GTV	32.85	24.08-45.38	4	
	Planning MR GTV	27.75	17.42-39.20	4	0.49
Oropharynx	Planning CT GTV	22.1	11.85-41.95	45	
	Planning MR GTV	20.9	10.30- 37.80	45	0.59
Larynx	Planning CT GTV	8.25	3.38-21.58	24	
	Planning MR GTV	10.35	4.13-24.85	24	0.44
Hypopharynx	Planning CT GTV	20.55	14.65-21.85	14	
	Planning MR GTV	20.6	14.18-28.63	14	0.8

Table 4. Showing Primary Sitewise Pearson Correlation between Planning CT &amp; Planning MRI GTVs among Pharyngeal and Laryngeal Carcinoma Patients

Primary site	r value	P value
Orophaynx	95.30 %	< 0.01
Nasopharynx	73 %	0.27
Larynx	97.70 %	<0.01
Hypopharynx	80 %	<0.01

significant correlation, except for Nasopharynx.

Bland Altman Plot showing that as mean GTV volume increases there is increase in difference between planning CT & MRI GTVs is shown in Figure 2.

Analysis was done to check whether there was difference in GTVs in planning CT and planning MRI in different T stage of tumor. There was no statistically significant difference in GTVs in different T stages of tumor and the same is shown in Table 5.

## Discussion

Median age of patients in our study was 62 years. Out of the total 87 patients, 82 (94%) were males. In our study around 45 (51.7%) of patients had oropharyngeal primary. Among the rest of the patients, 24 (27.6%) had laryngeal, 14 (16.1%) had hypopharyngeal and 4 (5.1%) had nasopharyngeal primary tumors. In study by Bird et al all 11 patients had Oropharyngeal primary [11]. In study by Daisne et al 13 out of 29 (45%) had laryngeal, 10 had

oropharyngeal and 6 had hypopharyngeal primary disease [7]. In study by Anderson et al 9 out of 14 (64%) patients had oropharyngeal primary disease [5].

In our study 62 (71%) patients had T3 or above tumor stages of disease. In our study 56 (64.3%) patients had node positive disease. But in this study we have looked at only the GTV of primary tumor and we have not seen the GTV of gross node. Various similar studies also studied volumes of primary tumor [7, 10, 11].

In this study median GTV with planning CT & MRI were 20.44 cc & 18.2 cc respectively. In our study sitewise GTVs with planning CT & MRI for different sites, Oropharynx (22.10 & 20.90) cc, Larynx (8.25 & 10.35) cc, Hypopharynx (20.55 & 20.6) cc and Nasopharynx (32.85 & 27.75) cc respectively. In study by Geet et al GTVs in planning CT by different observers ranged from 31.1 to 34.7 cc and with MRI it ranged from 29.4 to 31.5 cc for laryngeal tumors and for pharyngeal tumors it was 18.1 to 21.9 cc with CT and 19.3 to 21.8 cc with MRI respectively. This study did not show difference in volumes with CT and MRI [10]. Study by Daisne et al showed an average GTV for oropharyngeal with planning CT and MRI of 32.1 cc & 27.9 cc and for laryngopharyngeal primaries of 21.4 cc & 21.4 cc respectively. This study also did not demonstrate any difference in volumes with two modalities. In study by Bird et al mean GTVs for oropharyngeal tumors with CT & MRI were 11.9 & 12.7 cc and was documented as statistically significant [11]. Our study did not show any significant difference with CT & MRI GTVs as a whole and also on sitewise subset analysis. Our study also did

Table 5. T Stagewise Comparison of Median GTVs among Pharyngeal and Laryngeal Carcinoma Patients

T stage	No. of patients	Median Planning CT GTV	Median Planning MRI GTV	P value
T2	23	14.3	14.3	0.62
T3	48	20.45	19	0.54
T4a	4	16.55	27.45	0.69
T4b	10	50.75	52.4	1

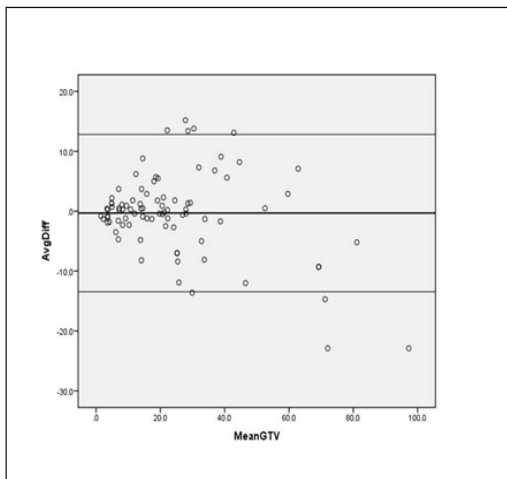


Figure 2. Bland Altman Plot Showing the Mean GTV and Average Differences among Pharyngeal and Laryngeal Carcinoma Patients

not show any significant difference in GTVs with two modalities as T (tumor) stage advanced. But as the mean GTV increased there was a trend towards difference in GTVs with two modalities.

As expected correlation analysis showed excellent positive correlation with GTVs of CT & MRI. For nasopharyngeal site primary the correlation value was less compared to other sites, possible reason could be lesser number of nasopharyngeal patients.

Study by Bird et al looked at intermodality and interobserver variation in target delineation in Oropharyngeal cancers with CT, MRI and PET CT. In this study GTVs were drawn by 5 physicians, including 2 radiologist and 3 radiation Oncologist [11]. Daisne et al studied target volumes in laryngopharyngeal tumors with different modalities such as CT, MRI and PET CT scan [7]. But in our centre as an institutional policy planning MRI is taken apart from CT simulation to aid in GTV delineation in Laryngopharyngeal tumors. In our centre PET CT is not regularly done for these patients. Hence with this study we investigated intermodality variation with CT & MRI only. In our study tumor volumes were drawn by a single radiation oncologist and we have not investigated interobserver variability.

PET CT was not used in our study as compared to similar studies. Our study did not investigate the interobserver variability. These are limitations of our study. But similar studies were done with less number of patients compared to our study and this adds to the strength of our study. In future we are planning for studies investigating interobserver, multiple modality variability in GTV delineation.

In conclusion, this study showed comparable median GTVs with planning CT & MRI of 20.4 & 18.2 cc respectively. Subset analysis did not show any significant difference in GTVs with two modalities for different primary tumor site. As expected there was good correlation between GTVs of two modalities in this study. Eventhough the results does not show significant

intermodality variation for GTV delineation, the difference in GTVs were bigger for larger tumors. With the results of this we cannot question the use of multiple modalities for GTV delineation as subtle variation in GTV can result in differences in target volumes resulting differences in toxicity profile. Future studies should be undertaken including other modalities like PET CT and also look for intermodality and interobserver variation in GTV.

## Acknowledgements

The authors acknowledge Dr Mohandoss for analyzing the data and reviewing the manuscript. The authors also acknowledge the other staffs of radiation oncology at the center.

## References

1. Landberg T, Chavaudra J, Dobbs J, Gerard J-, Hanks G, Horiot J-, Johansson K-, Möller T, Purdy J, Suntharalingam N, Svensson H. Report 62. Journal of the ICRU. 1999 Nov;os32(1):NP-NP. <https://doi.org/10.1093/jicru/os32.1.Report62>
2. David MB, Eisbruch A. Delineating neck targets for intensity-modulated radiation therapy of head and neck cancer. What we learned from marginal recurrences?. Frontiers of Radiation Therapy and Oncology. 2007;40:193-207. <https://doi.org/10.1159/000106036>
3. Eisbruch A, Marsh LH, Dawson LA, Bradford CR, Teknos TN, Chepeha DB, Worden FP, Urba S, Lin A, Schipper MJ, Wolf GT. Recurrences near base of skull after IMRT for head-and-neck cancer: implications for target delineation in high neck and for parotid gland sparing. International Journal of Radiation Oncology, Biology, Physics. 2004 05 01;59(1):28-42. <https://doi.org/10.1016/j.ijrobp.2003.10.032>
4. Schoenfeld GO, Amdur RJ, Morris CG, Li JG, Hinerman RW, Mendenhall WM. Patterns of failure and toxicity after intensity-modulated radiotherapy for head and neck cancer. International Journal of Radiation Oncology, Biology, Physics. 2008 06 01;71(2):377-385. <https://doi.org/10.1016/j.ijrobp.2007.10.010>
5. Anderson C, Sun W, Buatti J, Maley J, Policeni B, Mott S, et al. Interobserver and intermodality variability in GTV delineation on simulation CT, FDG-PET, and MR Images of Head and Neck Cancer. Jacobs J Radiat Oncol 2014;1:006.
6. Thiagarajan A, Caria N, Schöder H, Iyer NG, Wolden S, Wong RJ, Sherman E, Fury MG, Lee N. Target volume delineation in oropharyngeal cancer: impact of PET, MRI, and physical examination. International Journal of Radiation Oncology, Biology, Physics. 2012 05 01;83(1):220-227. <https://doi.org/10.1016/j.ijrobp.2011.05.060>
7. Daisne J, Duprez T, Weynand B, Lonneux M, Hamoir M, Reyckler H, Grégoire V. Tumor Volume in Pharyngolaryngeal Squamous Cell Carcinoma: Comparison at CT, MR Imaging, and FDG PET and Validation with Surgical Specimen. Radiology. 2004 Oct;233(1):93-100. <https://doi.org/10.1148/radiol.2331030660>
8. Hermans R, Feron M, Bellon E, Dupont P, Van den Bogaert W, Baert AL. Laryngeal tumor volume measurements determined with CT: A study on intra- and interobserver variability. International Journal of Radiation Oncology\* Biology\* Physics. 1998 02 01;40(3):553-557. [https://doi.org/10.1016/S0360-3016\(97\)00853-5](https://doi.org/10.1016/S0360-3016(97)00853-5)
9. Maroldi R, Battaglia G, Farina D, Maculotti P, Chiesa A.

- Tumours of the oropharynx and oral cavity: Perineural spread and bone invasion. *J Belge Radiol.* 1999;82:294-300.
10. Geets X, Daisne J, Arcangeli S, Coche E, De Poel M, Duprez T, Nardella G, Grégoire V. Inter-observer variability in the delineation of pharyngo-laryngeal tumor, parotid glands and cervical spinal cord: comparison between CT-scan and MRI. *Radiotherapy and Oncology: Journal of the European Society for Therapeutic Radiology and Oncology.* 2005 Oct;77(1):25-31. <https://doi.org/10.1016/j.radonc.2005.04.010>
  11. Bird D, Scarsbrook AF, Sykes J, Ramasamy S, Subesinghe M, Carey B, Wilson DJ, Roberts N, McDermott G, Karakaya E, Bayman E, Sen M, Speight R, Prestwich RJ. Multimodality imaging with CT, MR and FDG-PET for radiotherapy target volume delineation in oropharyngeal squamous cell carcinoma. *BMC Cancer.* 2015 Nov 04;15(1):844. <https://doi.org/10.1186/s12885-015-1867-8>



This work is licensed under a Creative Commons Attribution-Non Commercial 4.0 International License.