

Efficacy of Oral Pilocarpine for Reduction of Post Radiotherapy Xerostomia in Head and Neck Cancer Patients: A Prospective Randomized Institution-based Study

Shivangi Agrawal, Shivani Gupta, Ravinder Singh Gothwal, Ramraj Meena, Abhinav Kakkar

SMS Medical College and Attached Hospital, Jaipur, India.

Abstract

Purpose of study: To evaluate the efficacy and safety of oral pilocarpine concomitantly with radiation treatment for the prevention of radiation induced xerostomia in Head and Neck cancer patients. **Material and methods:** A prospective randomized study was carried out on 60 histopathological proven squamous cell cancer patients of Head and neck region. All patients received a total radiation dose of 66Gy /33 fraction/6.2 weeks (2Gy/fraction, 5 days/ week) on Telecobalt machine with or without concurrent chemotherapy. The concurrent chemotherapy eligible patients received, weekly chemotherapy courses using cisplatin 30 mg/m². Patients in the study group received oral pilocarpine 5.0 mg three times a day starting 3 days prior to start of radiotherapy and continued for 3 months post radiotherapy. Patients were evaluated on subjective basis based on Zimmerman Questionnaire and EORTC QLQ HN 35. The statistical analysis was done by Paired sample T test. **Results:** The average Zimmerman Xerostomia score for all parameters combined was as follows: First assessment -100mm vs 100mm; Second assessment -50mm vs 45mm; Third assessment -59mm vs 52mm; Fourth assessment -64mm vs 57mm, Fifth assessment -71mm vs 68. As per QLQ-HN 35 questionnaire used for assessment of quality of life of patients in both groups, we observed that better scores were obtained in the pilocarpine group in comparison to control group. **Conclusion:** In the present study, the effectiveness of Pilocarpine given during and 3 months post radiotherapy was observed in terms of better compliance during radiation treatment. Most of the patients had less subjective symptoms with lesser grades of toxicities observed during various phases of assessment post RT.

Keywords: Pilocarpine- head and neck cancer- radiotherapy- Xerostomia

Asian Pac J Cancer Care, 7 (3), 519-524

Submission Date: 07/04/2022 Acceptance Date: 08/14/2022

Introduction

The term “head and neck cancer”(HNC) refers to the cancers of upper aerodigestive tract, which includes the lips, oral cavity, oropharynx, sinonasal cavities, larynx, hypopharynx, nasopharynx and salivary glands.

Most HNC arise from the surface epithelium and are squamous cell carcinoma (SCC) or one of its variants (90%). Lymphomas and a wide variety of other malignant and benign neoplasms make up the remaining cases. Small cell neuroendocrine carcinoma presentation is quite rare in head and neck region [1,2].

Surgery and Radiotherapy are the only curative treatment modalities for head and neck carcinoma [3].

There are various factors on which the choice of modality depends including patient factors, primary site, clinical stage, and resectability of the tumor. Of all the cases, 30% to 40% of patients present with early-stage disease that is amenable to curative surgery or RT. More than 50% of patients present with locoregionally advanced disease at diagnosis. These patients can be treated with either complete surgical excision followed by postoperative RT with or without concomitant chemotherapy or concurrent chemoradiation. Although chemotherapy alone is not curative, it enhances the effects of radiation and thus is routinely used as a part of combined modality treatment

Corresponding Author:

Dr. Shivani Gupta
SMS Medical College and Attached Hospital, Jaipur, India.
Email: drshivani80@gmail.com

in patients with stage III and stage IV disease.

Radiotherapy alone can be a definitive treatment in early stages of Head and Neck cancer but is associated with acute and late toxicities that can have profound effects on patient's quality of life (QOL).

The most common long-term complication of RT and CRT is xerostomia i.e. subjective sensation of dry mouth which results because of damage to the salivary glands. The magnitude of xerostomia is dose-dependent, Parotid dysfunction is detectable at a 10-15Gy mean dose, and administration of an approximately 40-50 Gy mean dose can cause >75 % reduction in its function [4].

Radiation-induced xerostomia can start early during treatment: a 50% to 60% decrease in salivary flow can be observed in the first week; and, after 7 weeks of conventional RT, salivary flow reduces to approximately 20%. Apparently, there is only loss of function of saliva producing cells with no decrease in the cell count during the first days after irradiation.

Konings et al in his study proposed 2 separate mechanisms to explain radiation- induced salivary gland dysfunction [5]. First, there is a defect in cellular functioning because of selective membrane damage, confounding the receptor- mediated signaling pathways of water excretion. No immediate cell death or lysis takes place. The classical cell killing of progenitor cells and stem cells has been found to be responsible for late damage, thus inhibiting proper cell renewal, and damage to the cellular environment, leads to shortage of properly functioning secretory cells.

For up to several months after RT, salivary function continues to decline. The recovery is possible until 12-18 months of RT which depends upon various factors including dose received by the salivary glands and the volume of the gland tissue included in the irradiation fields, however, xerostomia usually develops into an irreversible, life-long problem.

There are many methods in use for the prevention of radiation induced xerostomia such as frequent liquid intake, sugar free candies and systemic sialogogues. Pilocarpine is currently the sole sialogogic agent approved by the FDA for radiation-induced xerostomia [6]. Pilocarpine is a naturally occurring alkaloid which primarily functions as a muscarinic-cholinergic agonist with mild β -adrenergic activity; as a parasympathomimetic agent, it causes stimulation of cholinergic receptors present on the surface of exocrine glands, which results in diaphoresis, salivation, lacrimation, and pancreatic secretion. For optimal results, it is necessary to start the patient on pilocarpine 3 days prior to radiation treatment and continue it for a period of 8 to 12 weeks after radiotherapy at the dose of 5mg 3 times daily.

Pilocarpine is contraindicated in various conditions such as in patients who have asthma, acute iritis, or glaucoma and should be used with extreme caution in patients who have chronic obstructive pulmonary disease (COPD) and previous history of cardiovascular disease.

In this clinical trial, we aim to evaluate the role of pilocarpine in the reduction of post radiotherapy xerostomia.

Objective

- To compare the quality of life as per the ZIMMERMAN QUESTIONNAIRE QLQ HN35 questionnaire in both comparison groups with and without pilocarpine.

- To compare the grades of toxicities in these cases as per the RTOG criteria in both comparison groups.

Materials and Methods

This is a prospective randomized study in which newly diagnosed cases of Head and neck malignancy were given curative radiation treatment with or without concurrent cisplatin in control arm (ARM-B) along with pilocarpine in study arm (ARM -A). The patients included were histologically proven squamous cell carcinoma of head and neck region within the age group of 30-60 years with an ECOG performance status of 0-2. The patient's had adequate baseline parameters Table 1 describes the patients characteristics. The study included those patients who were willing to sign the written informed consent .

Patients having distant metastasis, postoperative patients, patients diagnosed with nasopharyngeal or salivary gland malignancy, patients on palliative radiotherapy, patients who had received radiotherapy or chemotherapy earlier, patients having contraindication to the use of pilocarpine (uncontrolled asthma, narrow angle glaucoma, severe hepatic impairment), pregnant or lactating mothers, patients with other comorbidities, patients with deranged LFTs, RFTs, haematological tests, and HbSAg, HIV positive patients were excluded from the study.

Radiotherapy

All patients were treated with External beam Radiotherapy on teletherapy Co-60 Machine by 2 lateral opposed fields.

All patients received a total radiation dose of 66Gy /33 fraction/6.2 weeks (2Gy/fraction, 5 days/ week) on Telecobalt machine with or without concurrent chemotherapy. Patients were treated by 2 lateral opposed fields in 3 phases. In first phase, the patients received total dose of 44 Gy covering the posterior nodal group. In second phase, radiotherapy field was reduced in size so as to spare the spine up to the dose of 60Gy. In the third phase boost dose of 6-10 Gy was given. Patients in the test group received oral pilocarpine starting 3 days prior to start of radiotherapy and continued for 3 months post radiotherapy.

Concurrent Chemotherapy

The concurrent chemotherapy eligible patients received weekly chemotherapy courses using cisplatin 30 mg/m². This was usually started concurrently with radiotherapy and six courses were given.

Evaluation after completion of treatment and follow up

Patients were evaluated for mucositis/xerostomia at 1, 3 ,6 and 12 months. Patients were evaluated on subjective basis based on Zimmerman Questionnaire [7] and EORTC QLQ HN 35 [8]. The Zimmerman Xerostomia

Questionnaire includes parameters like dryness of mouth and tongue, comfort status of mouth and tongue; sleep impairment attributed to dryness of mouth, speech impairment attributed to dryness of mouth and difficulty in denture wearing.

CECT head and neck was obtained on any clinical suspicion of either local recurrence or metastasis. Toxicity was graded as per RTOG/EORTC [9] criteria.

Results

The purpose of this study was to evaluate the preventive effect of pilocarpine on radiation induced xerostomia in patients with head and neck cancers.

The radiation reactions in both study and control groups were observed. They were as follows:

Mucosal reactions: Grade I: 1 (3.3%) vs 0%, Grade II: 10 (33.3%) vs 10 (33.3%) Grade III: 19 (63%) vs 20 (66%) (Figure 1).

Cutaneous reaction: Grade I: 2 (6.6%) vs 1 (3.33%) Grade II: 3 (10%) vs 2 (6.6%) Grade III: 25 (83%) vs 27 (90%) (Figure 2).

Complete response in study group was 56.6 % whereas in control group ,it was found to be 63.3%. Partial response was 43.3 % in study group compared to 39% in control group.

Zimmerman Xerostomia scores for various parameters in the pilocarpine (study) group in comparison with control group respectively have been shown in (Table 2). As high as the Zimmerman Xerostomia score was

found on the scale of 0-100, the better salivary gland function was observed. The average Zimmerman Xerostomia score for all parameters combined including dryness of mouth and tongue, comfort status of mouth and tongue, sleep impairment, speech impairment and difficulty in chewing and swallowing (Figure 3), of the study group as compared to the control group was as follows: First assessment -100mm vs 100mm; Second assessment -50mm vs 45mm; Third assessment -59mm vs 52mm; Fourth assessment -64mm vs 57mm, Fifth assessment -71mm vs 68mm. There was overall trend of better salivary gland function in study group as compared to control group (Table 2).

QLQ HN-35 scoring for assessment of quality of life of patients in both study and control group was used. The results have been depicted in Table 3 and Figure 4.

Discussion

This randomized, prospective study was conducted to assess the effectiveness of oral pilocarpine in preventing xerostomia among patients receiving radiotherapy for head and neck cancers. The results of our study have shown that the prophylactic oral use of pilocarpine can reduce severity of radiation induced xerostomia and dry mouth in these patients.

Xerostomia is a major complication having a major impact on QOL in patients who are receiving curative radiotherapy for head and neck cancer. As there is no threshold dose, the magnitude depends both on the

Table 1. Patients' Characteristics in Radical Radiotherapy in HNC

Characteristics		Patient Group	
		Pilocarpine group n=30	Control Group n=30
Age (years)	Range	30-60	30-60
	Mean	47	49
Gender	Male	26	25
	Female	4	5
	M:F Ratio	6.5:1	5:01
ECOG SCORE	0	13 (43%)	10 (33%)
	1	9 (30%)	8 (27%)
	2	8 (27%)	12 (40%)
Tumor stage (AJCC 8 th)	I	0	0
	II	6	2
	III	13	11
	IV	11	17
Primary site	Oral Cavity	8	10
	Oropharynx	11	3
	Hypopharynx	2	5
	Larynx	9	12
Histopathology	WDSCC	12	14
	MDSCC	9	10
	PDSCC	9	6

Table 2. Assessment of Patients based on Zimmerman Scoring System

	First assessment		Second Assessment		Third assessment		Fourth assessment		Fifth assessment	
	A	B	A	B	A	B	A	B	A	B
Dryness of mouth	100	100	50	45	59	52	64	57	71	68
Sleep impairment	100	100	67	62	72	67	75	69	79	73
Comfort status of mouth	100	100	44	41	53	48	55	49	63	57
Speech Impairment	100	100	51	48	64	57	64	58	71	63
Difficulty in eating	100	100	46	43	53	47	63	53	68	66

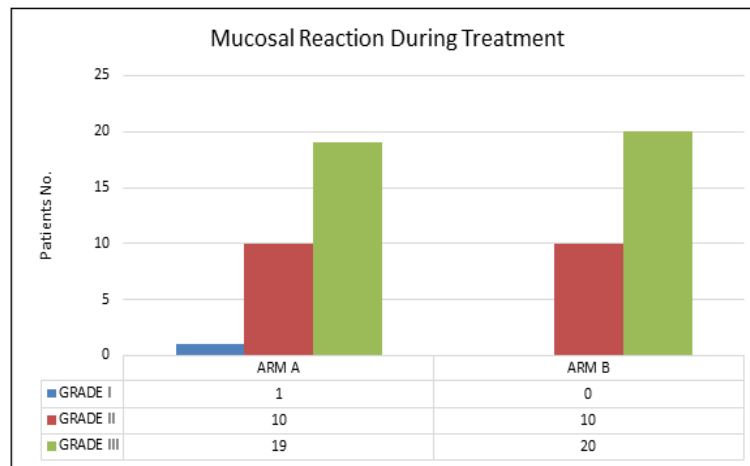


Figure 1. Assessment of Mucosal Reactions During the Radiation Treatment

volume of salivary tissue irradiated and dose of radiation delivered. Xerostomia and its associated symptoms have a considerable, negative global impact, resulting in shame, anxiety, disappointments and verbal communication difficulties [10-12].

During radiotherapy mucosal and cutaneous toxicities were noted (Figure 1 and 2). Most of them were Grade II/III toxicities in ARM A patients whereas, in ARM B, most of the patients had Grade III toxicity. Complaint of dysphagia and requirement for Ryle's tube insertion was more common in patients who didn't receive Pilocarpine. Warde et al. in their study observed no difference in severity of acute reactions during RT [12]. In RTOG 97-09 no difference was noted in mucositis score as patients in both arms required nutritional supplementation [13].

At the end of second assessment i.e., one month post RT patients were assessed based on Zimmermann xerostomia questionnaire and EORTC QLQ H&N 35

questionnaire. According to Zimmermann score, patients in pilocarpine group had lesser grades of mucositis and swallowing difficulties in comparison to control group (p value <0.00001). The results were also confirmed by the EORTC QLQ HN 35 questionnaire. The ARM A study group tolerated radiotherapy with lesser symptoms as compared to ARM B.

At the end of third assessment, i.e. three months post radiation treatment, there was decrease in symptoms in both arms but the salivary function was better preserved in pilocarpine group. The mean xerostomia score was 59 mm vs 52 mm in ARM A and ARM B respectively (p value <0.00001). There were minor side effects related to the usage of pilocarpine, but none led to the discontinuation of the drug. This subjective relief was also confirmed by the EORTC questionnaire in which patients in ARM A had significantly better symptomatic relief three months post RT which included lesser intake of analgesics, decreased

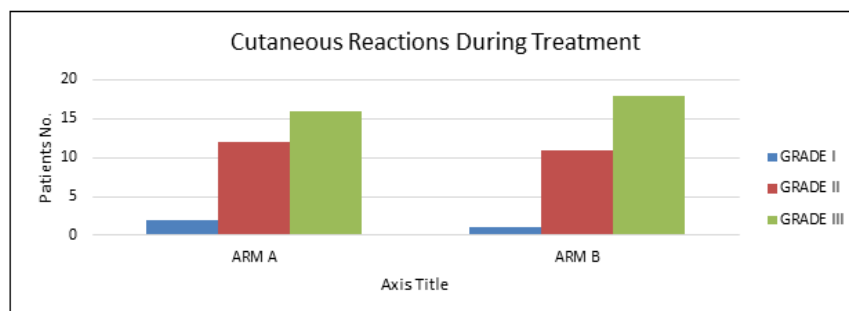


Figure 2. Cutaneous Reactions During Radiation Treatment

Table 3. Assessment of Patients (n=60) based on QLQ HN-35

	First assessment		Second assessment		Third assessment		Fourth assessment		Fifth assessment	
	A	B	A	B	A	B	A	B	A	B
Pain	5.6	5	52.6	64	43	56	35	50	24	30
Swallowing difficulty	6	6.2	65	76	34	35	32	32	24	38
Dental problems	10.2	15	15	18	12	20	16	24	12	22
Fatigue	20	26	55	58	39	47.5	32	44	28	40
Dry mouth	5	5.5	24	28	20	25	24	44	22	48
Difficulty Opening Mouth	12	14.5	67	70	33	45	22	40	20	30
Sleep impairment	20	18	56	67	25	30	20	28	20	29
Analgesics	30	34	72	74	58	65	48	50	39	49

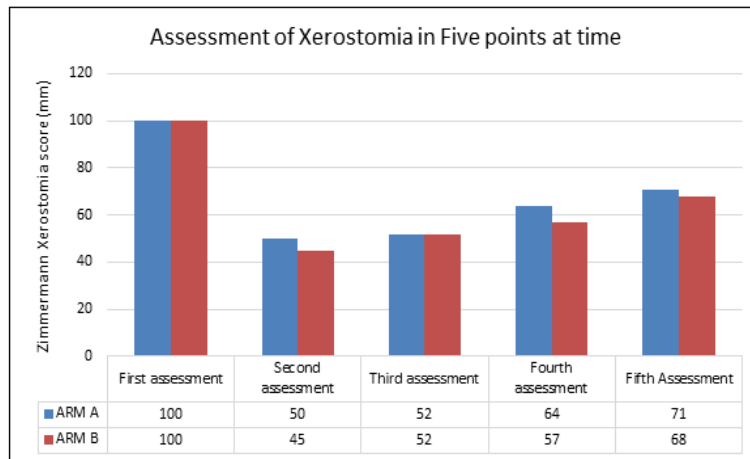


Figure 3. Average Zimmerman Xerostomia Score (n=60) in Radical Radiotherapy for Head & Neck Cancer

difficulty in swallowing and better sleep leading to better QOL (p value<0.00001).

At the end of fourth assessment i.e., six months post RT, there was borderline statistically significant difference in dryness of mouth in both the arms (p value <0.52) with lesser grade of xerostomia in ARM A in comparison to ARM B (p value <0.00001). Although there was no significant difference in swallowing difficulties in both the arms (p value <0.01), overall better QOL was noted in

ARM A as compared to ARM B (in terms of better sleep and less intake of analgesics.)

At the end of fifth assessment i.e., one year post RT, patients in both arms experienced various grades of xerostomia but more severe grade i.e., Grade III/ IV was noted in ARM B as compared to ARM A in which Grade II/ III toxicity was noted. Zimmermann et al. concluded that use of pilocarpine concomitantly with RT and 3 months thereafter reduced radiation induced xerostomia

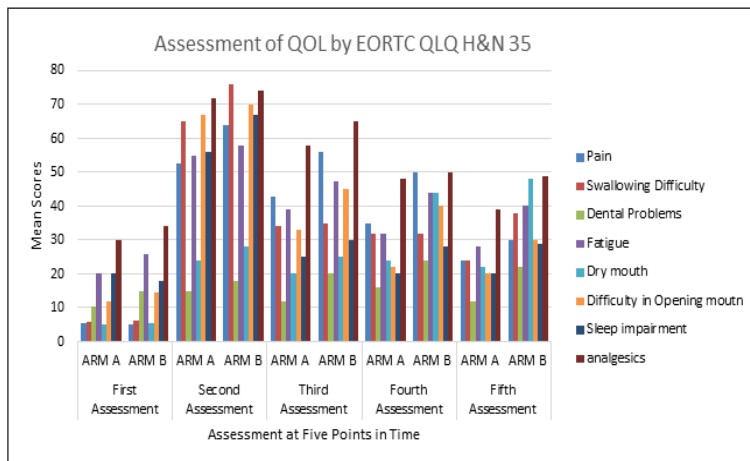


Figure 4 . Average EORTC QLQ HN-35 Score in Radical Radiotherapy of HNC Patients

and resulted in better QOL [7]. Haddad et al. proved that use of pilocarpine in comparison to placebo could lead to a significant diminishment of subsequent radiation-induced xerostomia [14]. In RTOG 97-09 trial they found that following the completion of radiation therapy, the average unstimulated salivary flow was statistically greater in the pilocarpine group, whereas no difference was noted following parotid stimulation. There was no effect on the amelioration of mucositis. The results of the QOL scales did not reveal any significant difference between the pilocarpine and placebo groups with regard to xerostomia and mucositis. The significant difference in unstimulated salivary flow supports the concomitant use of oral pilocarpine to decrease radiation-associated xerostomia [15].

Thus we can conclude that concomitant use of pilocarpine can lead to lower frequency of oral symptoms during treatment thus leading to better tolerability of radiation treatment. The use of pilocarpine is associated with lesser grades of xerostomia post RT leading to lesser oral symptoms, better quality sleep thus leading to improved QOL.

In conclusion, the effectiveness of Pilocarpine given during and 3 months post Radiotherapy was observed in terms of better compliance during radiation treatment. Most of the patients had less subjective symptoms with lesser grades of toxicities observed during various phases of assessment post RT. There was borderline statistical difference in terms of xerostomia one year post RT, but other QOL parameters such as sleep impairment, chewing difficulties, speech difficulties were less in pilocarpine group.

References

1. McAfee WJ, Morris CG, Amdur RJ, Werning JW, Mendenhall WM. Definitive radiotherapy for juvenile nasopharyngeal angiofibroma. *American Journal of Clinical Oncology*. 2006 04;29(2):168-170. <https://doi.org/10.1097/01.coc.0000203759.94019.76>
2. Ward JR, Feigenberg SJ, Mendenhall NP, Marcus RB, Mendenhall WM. Radiation therapy for angiosarcoma. *Head & Neck*. 2003 Oct;25(10):873-878. <https://doi.org/10.1002/hed.10276>
3. Winquist E, Agbassi C, Meyers BM, Yoo J, Chan KKW. Systemic therapy in the curative treatment of head and neck squamous cell cancer: a systematic review. *Journal of Otolaryngology - Head & Neck Surgery = Le Journal D'oto-Rhino-Laryngologie Et De Chirurgie Cervico-Faciale*. 2017 04 04;46(1):29. <https://doi.org/10.1186/s40463-017-0199-x>
4. Bussels B, Maes A, Flamen P, Lambin P, Erven K, Hermans R, Nuyts S, Weltens C, Cecere S, Lesaffre E, Van den Bogaert W. Dose-response relationships within the parotid gland after radiotherapy for head and neck cancer. *Radiotherapy and Oncology: Journal of the European Society for Therapeutic Radiology and Oncology*. 2004 Dec;73(3):297-306. <https://doi.org/10.1016/j.radonc.2004.09.015>
5. Konings AWT, Coppes RP, Vissink A. On the mechanism of salivary gland radiosensitivity. *International Journal of Radiation Oncology, Biology, Physics*. 2005 07 15;62(4):1187-1194. <https://doi.org/10.1016/j.ijrobp.2004.12.051>
6. Kałużny J, Wierzbicka M, Nogala H, Milecki P, Kopeć T. Radiotherapy induced xerostomia: mechanisms, diagnostics, prevention and treatment--evidence based up to 2013. *Otolaryngologia Polska = The Polish Otolaryngology*. 2014 02;68(1):1-14. <https://doi.org/10.1016/j.otpol.2013.09.002>
7. Zimmerman RP, Mark RJ, Tran ML, et al. Timing of pilocarpine treatment during head and neck radiotherapy: concomitant administration reduces xerostomia better than post-irradiation pilocarpine. *Int J Radiat Oncol Biol Phys*. 1996;37(3):571-575.
8. Hjerstad MJ, Fayers PM, Bjordal K, Kaasa S. Health-related quality of life in the general Norwegian population assessed by the European Organization for Research and Treatment of Cancer Core Quality-of-Life Questionnaire: the QLQ=C30 (+ 3). *Journal of Clinical Oncology: Official Journal of the American Society of Clinical Oncology*. 1998 03;16(3):1188-1196. <https://doi.org/10.1200/JCO.1998.16.3.1188>
9. Cox JD, Stetz J, Pajak TF. Toxicity criteria of the Radiation Therapy Oncology Group (RTOG) and the European Organization for Research and Treatment of Cancer (EORTC). *International Journal of Radiation Oncology, Biology, Physics*. 1995 03 30;31(5):1341-1346. [https://doi.org/10.1016/0360-3016\(95\)00060-C](https://doi.org/10.1016/0360-3016(95)00060-C)
10. Castelijns JA, Gerritsen GJ, Kaiser MC, Valk J, Jansen W, Meyer CJ, Snow GB. MRI of normal or cancerous laryngeal cartilages: histopathologic correlation. *The Laryngoscope*. 1987 09;97(9):1085-1093. <https://doi.org/10.1288/00005537-198709000-00016>
11. Leslie A, Fyfe E, Guest P, Goddard P, Kabala JE. Staging of squamous cell carcinoma of the oral cavity and oropharynx: a comparison of MRI and CT in T- and N-staging. *Journal of Computer Assisted Tomography*. 1999 02;23(1):43-49. <https://doi.org/10.1097/00004728-199901000-00010>
12. Imola MJ, Gapany M, Grund F, Djalilian H, Fehling S, Adams G. Technetium 99m single positron emission computed tomography scanning for assessing mandible invasion in oral cavity cancer. *The Laryngoscope*. 2001 03;111(3):373-381. <https://doi.org/10.1097/00005537-200103000-00003>
13. Warde P, O'Sullivan B, Aslanidis J, Kroll B, Lockwood G, Waldron J, Payne D, Bayley A, Ringash J, Kim J, Liu F, Maxymiw W, Sprague S, Cummings BJ. A Phase III placebo-controlled trial of oral pilocarpine in patients undergoing radiotherapy for head-and-neck cancer. *International Journal of Radiation Oncology, Biology, Physics*. 2002 09 01;54(1):9-13. [https://doi.org/10.1016/s0360-3016\(02\)02890-0](https://doi.org/10.1016/s0360-3016(02)02890-0)
14. Haddad P, Karimi M. A randomized, double-blind, placebo-controlled trial of concomitant pilocarpine with head and neck irradiation for prevention of radiation-induced xerostomia. *Radiotherapy and Oncology: Journal of the European Society for Therapeutic Radiology and Oncology*. 2002 07;64(1):29-32. [https://doi.org/10.1016/s0167-8140\(02\)00104-4](https://doi.org/10.1016/s0167-8140(02)00104-4)
15. Fisher J, Scott C, Scarantino CW, Leveque FG, White RL, Rotman M, Hodson DI, Meredith RF, Foote R, Bachman DG, Lee N. Phase III quality-of-life study results: impact on patients' quality of life to reducing xerostomia after radiotherapy for head-and-neck cancer--RTOG 97-09. *International Journal of Radiation Oncology, Biology, Physics*. 2003 07 01;56(3):832-836. [https://doi.org/10.1016/s0360-3016\(03\)00121-4](https://doi.org/10.1016/s0360-3016(03)00121-4)



This work is licensed under a Creative Commons Attribution-Non Commercial 4.0 International License.